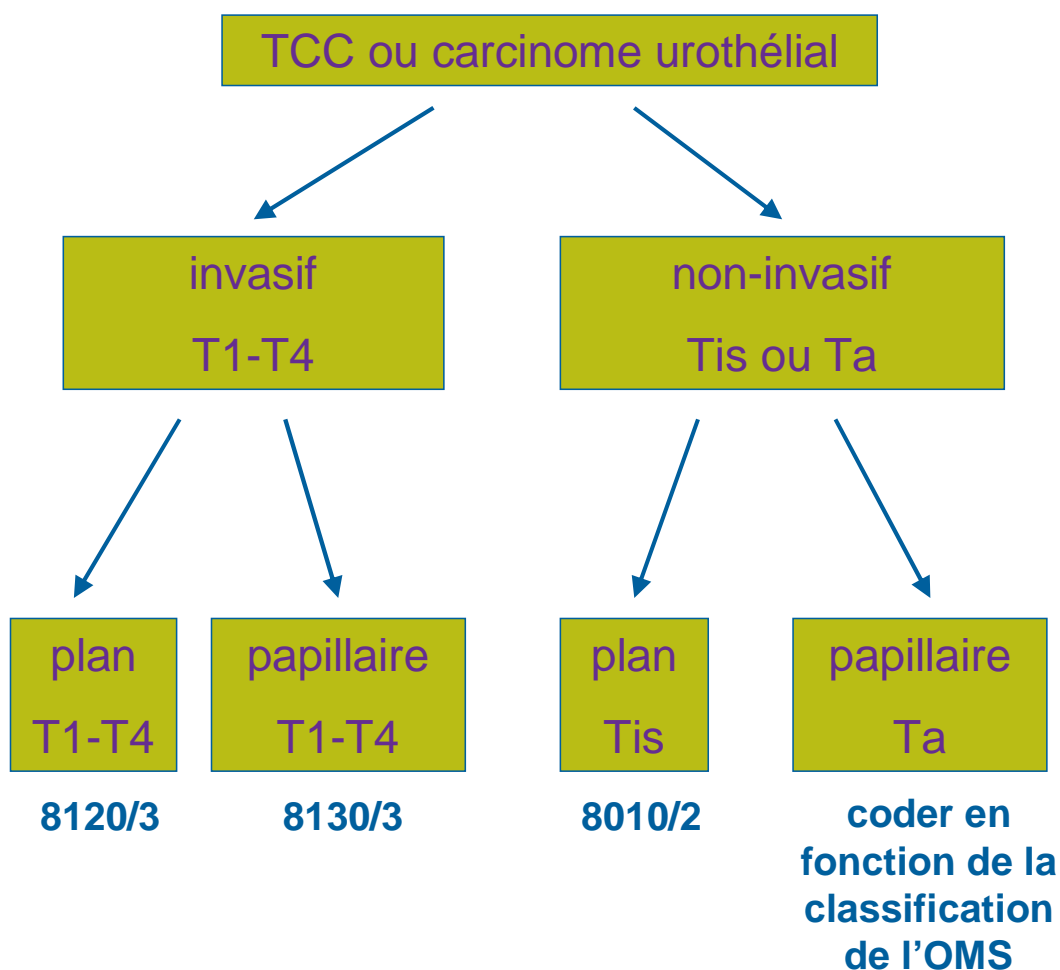


Tumeurs urothéliales: invasives ou non invasives?(3)



TCC ou carcinome urothélial

